

DENTIGEROUS CYSTS AN AVOIDABLE CATASTROPHE

Some dental problems just happen despite all best efforts. Labs will break teeth, border collies will wear their teeth down, toy poodles will get periodontal disease, Shih Tzus will suffer mandibular fractures as a result of being out in a strong wind. There is one problem, however, that is 100% avoidable; and avoid it we must. This would be the dentigerous cyst.

By definition, a *dentigerous cyst* (in a dog or cat) is a fluid-filled cyst surrounding the crown of an unerupted tooth. This is in contrast to the equine version, which I will not be discussing.

It is time for some background. When a tooth is in the early developmental stages, there is a multilayered sac of tissue surrounding the primordial dental pulp. This sac, known as the *enamel organ*, covers the pulp like a toque* without the pompom. The outer layer is *the outer enamel epithelium*. Inside this is the *stellate reticulum*. The inner surface, in contact with the pulp, is the *inner enamel epithelium*, made up of the *ameleoblasts*. These are the cells responsible for the production and mineralization of the enamel that covers the crown of the tooth.

Once the coronal enamel has been formed, the enamel organ has out-lived its purpose and it shuts down. The stellate reticulum atrophies and the outer enamel epithelium collapses onto the inner enamel epithelium. At this point, the structure becomes the *reduced enamel epithelium*.

When the tooth erupts and the crown breaks through the gingiva, most of the outer enamel epithelium is torn away. A small ring of it persists near the junction of the crown and root to form part of the gingival attachment (*the junctional epithelium*). It is no longer a closed sac, but a collar of tissue surrounding the neck of the tooth.

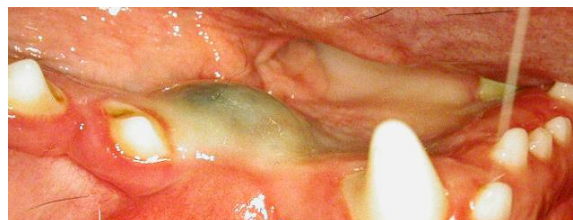toque, *n.* 1 /tu:k/ *Cdn* a a close-fitting knitted hat, often with a tassel or pompom on the crown.

But what happens if the tooth fails to erupt? Sometimes nothing happens. Sometimes the tooth and its surrounding tissues just lie dormant in the bone. Sometimes the tooth is absorbed. Sometimes something far worse happens.

As cells from the inner enamel epithelium desquamate into the lumen of the sac, an osmotic gradient develops and fluid is pulled in, causing the sac to expand. As it expands, it causes pressure atrophy of the surrounding bone. Left alone, these cysts will just keep expanding indefinitely, destroying everything in their way. Within a very short time, they can destroy the support for adjacent teeth and weaken the jaw to the brink of pathological fracture. They can also cause external resorption of the roots they come into contact with.

By the time these cysts grow large enough to be detected by the owner or by the naked-eye on clinical examination, much irreversible damage is done and the necessary surgery can be quite involved. Specifically, it involves removal of the offending unerupted tooth, any adjacent teeth that have lost their periodontal support or have other radicular pathology and removal of the cyst lining from what is often a complex and convoluted cavern.

Here is a clinical photo of a typical cyst in a young boxer. Note the definite blue hue to the overlying soft tissue. (If you are reading the B&W hardcopy of *The CUSP*, go to www.toothvet.ca to view the full-colour pdf version.) This cyst has broken through the bone and the bluish area would be flocculent.



The good news is that dentigerous cysts are completely preventable and once you have read this article, you will never let one happen again. As is so often the case, the

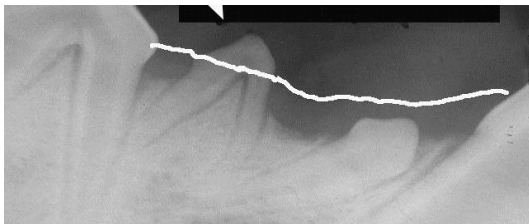
key lies in a) knowing normal anatomy, b) looking carefully for abnormalities and c, d, e and f) taking intra-oral dental radiographs when there is even the slightest doubt. If the radiographs reveal an unerupted tooth, get it out before a cyst has a chance to form. Problem averted and you are a hero because you just saved your client hundreds of dollars.

Here's the deal. When you have a patient in at about six-months of age for spay/neuter always do a thorough oral inventory. There are many problems you might find and manage by routinely doing this, but let's stick to dentigerous cysts for now.

A cat is supposed to have 30 adult teeth. A dog is supposed to have 42. If you find less than this number, something is amiss. Maybe the adult teeth in question are actually missing and this requires only that you record the findings in the permanent record so you never have to wonder about it (them) again. On the other hand, maybe that 'missing' tooth is not missing at all but is hiding (impacted or unerupted). If the tooth is unerupted there are a few options to consider depending on which tooth it is, where it is located, what direction it is pointing in and how far along the patient is in its oral development.

In a previous issue I discussed soft tissue impactions and how to deal with them. In those cases, the teeth have a good chance of erupting normally with a little surgical help (see <http://www.toothvet.ca/PDFfiles/softimpact.pdf>).

In this piece I would like to consider a few examples of teeth that are not going to be able to erupt no matter what we do. You will then be able to extrapolate to the various clinical presentations you come across.



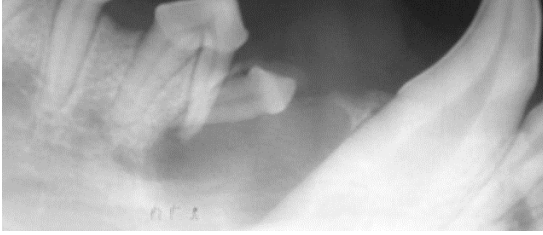In the image at the bottom of the last column, we see three abnormalities of note as well as some other useful information about this patient. For orientation, the image is of the right mandible showing portions of the canine tooth (to the right), the first and second premolar and much of the third premolar.

The first abnormality I want to point out is that the tooth indicated by the large arrow is the primary (deciduous, baby) second premolar and there is no adult (permanent, secondary, successional) second premolar to replace it. As a side note, I do not find that primary teeth do well in the long term in an adult mouth and so even though this tooth looks radiographically healthy now, I would remove it as a "target of opportunity".

We can see that the pulp chamber of the canine tooth (dark area inside the tooth) is very wide and the dentin wall of the root is very thin. The first and third premolars also have relatively large pulp chambers. This all indicates that either a) the patient is young [likely] or b) all three of these teeth suffered pulp necrosis when the dog was young [less likely]. Have a look at <http://www.toothvet.ca/PDFfiles/endo.pdf> for more detail on this pulp-chamber-size thing.

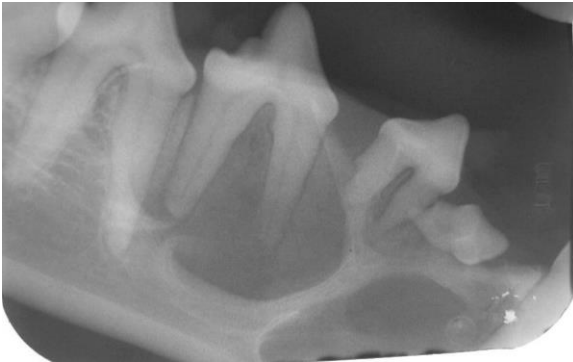
The first premolar should be standing perpendicularly. It is not. It is a lazy tooth, lying down on the job. The white line depicts the dorsal extent of the gingival margin and so it is plain to see that this first premolar has not broken through the gingiva. We can, therefore assume that the reduced enamel epithelium remains as a closed sac encompassing that unerupted crown. This tooth is a prime candidate to form a dentigerous cyst, wrecking havoc with the mandible in the region.

Here is a pre-operative radiograph of what can happen if this unerupted first premolar is left in place.



The radiograph is of the right mandible of a one-year-old golden retriever. The dark area all around the first premolar and encompassing the mesial root of the second premolar is the fluid-filled cyst.

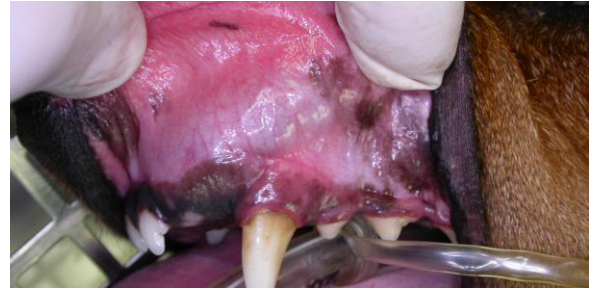Here is one from an eleven-month-old Lhasa.



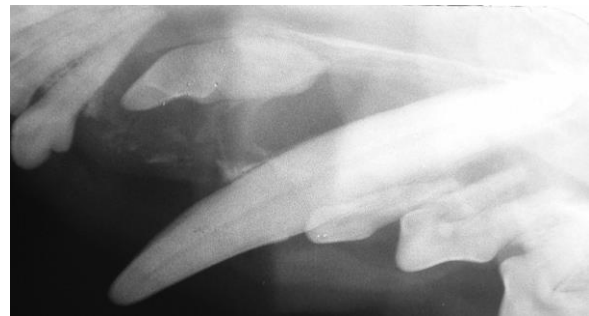You can see that this cyst is quite complex in its outline. You can also see that it has destroyed the bone support for the canine tooth, the second, third and some of the fourth lower premolar as well as causing some external root resorption of the premolars. The canine and all four premolars were extracted during the surgery to remove this cyst.

The following images are from the rostral maxilla and incisive area of a five-and-a-half year old Dachshund. The dog was presented

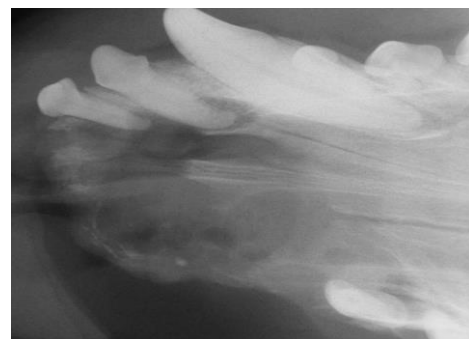
for evaluation and treatment of a maxillary swelling.



Here we see the typical blue hue to the swelling. We can also see that the adult third incisor is apparently absent. According to the history, a tooth recently fell out at this location. Now let's see what the radiograph shows.

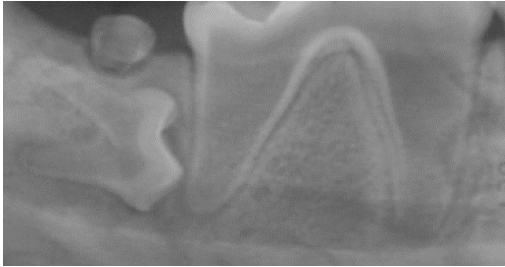


So the missing adult third incisor was not missing at all. It was just hiding. What recently fell out must have been the persistent primary third incisor. This cyst in this dog's face was so large that treatment involved removal of all maxillary incisors as well as the left maxillary canine and first premolar. Here is an intra-operative radiograph of the area before I removed the last two incisors.



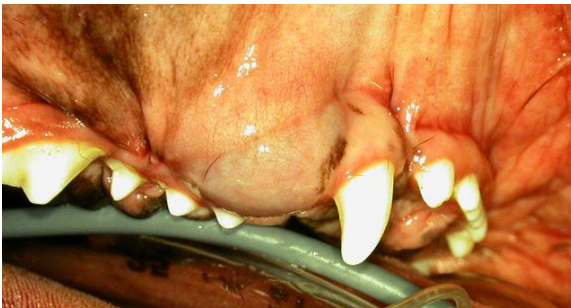Back to how to prevent these. As I was saying, do a thorough oral inventory of

every patient in for spay/neuter (or any other time you get a chance) and if anything looks even slightly out of the ordinary, get intra-oral dental radiographs. If you find an unerupted tooth (such as this one...



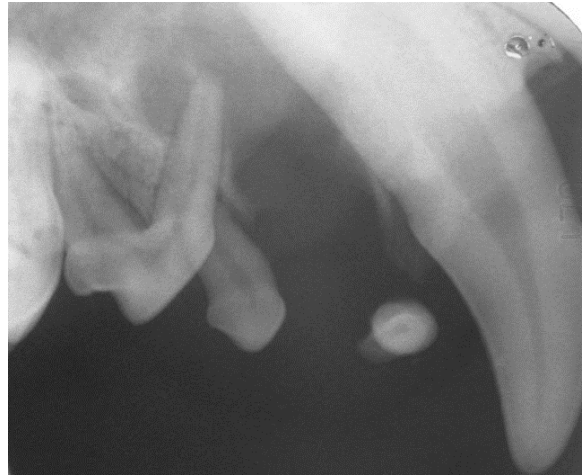...remove it or have it removed ASAP before it has a chance to start forming a cyst and causing collateral damage to surrounding structures.

Here is a major exception to the rule. If you are examining a boxer, I don't care how many teeth it seems to have, always do intra-oral dental radiographs, especially of the incisor and premolar areas. For some reason, boxers are very prone to having supernumerary incisors (especially uppers) and first premolars (again mostly in the upper jaw). Lots of boxers I see have two or even three first premolars per quadrant and often one or more is un-erupted. The next case is a one-year-old boxer with a maxillary swelling. Historically, the referring veterinarian had aspirated a straw-coloured fluid from this lesion several times over the months prior to referral. Visual examination reveals a normal number of teeth all nicely erupted. But there is that persistent swelling behind the canine tooth, again with the typical bluish cast.



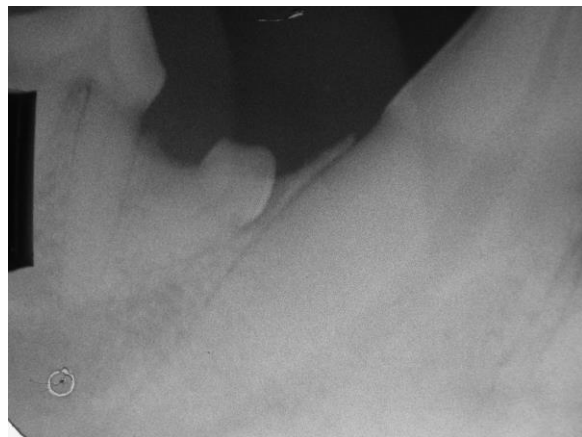
What ever shall we do???

By now you must know that the first thing to do is to get an intra-oral dental radiograph and here it is.



The image shows an unerupted supernumerary right maxillary first premolar tooth floating around in the cyst caused by its presence. In this case, we only lost the two first premolars and the second premolar on this side. However, the problem was bilateral and so we had to do the same on the left side.

Now, sometimes you will come across an unerupted tooth incidentally in a mature animal such as in this film.

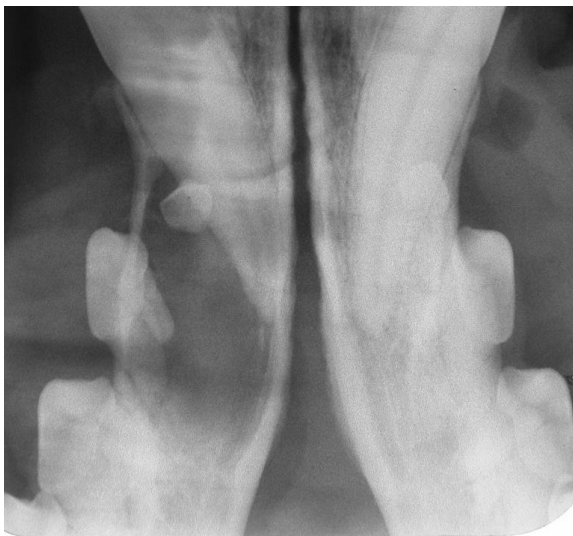


The patient is a three-and-a-half year old golden. If this were the only abnormality and I was not already doing surgery in this mouth, I would not have been completely wrong to leave this tooth in place. After all, it has been there for over three years without forming a cyst and so it maybe never will. All the other cysts I have treated started

much earlier. The longer an unerupted tooth goes without forming a cyst, the less likely it is that it ever will form one.

If I find an unerupted tooth in a ten-year-old dog, I am quite happy to leave it be. However, I will always radiograph, document and discuss with the owners before making that decision and I will always follow the tooth radiographically until the day I either remove it or the animal passes away. On the other hand, if I am doing surgery in the area anyway and the unerupted tooth is going to be quick and easy to pop out, I would likely remove it pro-actively and then never have to worry about it again. This is one of the 'gray areas' in dental treatment planning.

In the case of this young adult, he had a massive cyst in the left mandible that required surgery and so I took this quiet-looking premolar out of the right mandible as well. Below is the cyst. Treatment involved removal of the unerupted first premolar and the second premolar along with curettage of the cyst lining. I placed a synthetic bone graft in the defect in the hope of preserving the canine tooth. On follow-up, the tissues around the canine tooth had healed well and it was in fine periodontal shape, but it had suffered pulp necrosis and so required root canal therapy. Presumably the cyst or the surgery to remove it disrupted the blood supply to the pulp.



In conclusion, I want you to do the following:

- always look for and investigate any dental abnormalities at every opportunity.

- take lots of intra-oral dental radiographs (you will be amazed at the pathology you will uncover doing this).

- if you find an unerupted tooth in a young animal, get it out ASAP before it can form a large, destructive dentigerous cyst.

- if you find an unerupted tooth in a mature animal and there is no evidence of cyst formation, weigh the options and make an informed clinical decision to either remove it pro-actively or document and monitor it radiographically on a regular basis.

- in boxers, even if the tooth-count seems normal, get the radiographs to look for surprises.

As always, I am here to deal with any of the patients that you feel are beyond your comfort level.